

Procedure PUNCH AND SHAVE BIOPSY

Robert M. Howse, Jr.

Indications

1. Shave biopsy: epidermal lesions such as seborrheic dermatoses, actinic keratoses, warts, skin tags, scabies
2. Punch biopsy: epidermal, intradermal lesions such as carcinoma, infection, nevi, and autoimmune, parasitic, and pyogenic granulomas

Contraindications

1. Highly vascular lesions, such as hemangioma
2. Benign or self-limited lesions, such as strawberry hemangioma
3. Referral and special treatment required, such as cavernous hemangioma, extensive facial basal cell or squamous cell carcinoma

Preparation

Patient history and education about lesion, anesthesia, procedure, risks of bleeding, infection, scarring, benefits, follow-up, signature and witness on informed consent, wound care, cosmetic procedures

1. Bleeding history
 - a. *Aspirin*: Prophylactic doses of 325 mg or less a day seldom prevent hemostasis; higher doses may delay hemostasis but can be managed with 10 to 15 minutes of postoperative pressure.
 - b. *Coumarin*: If the prothrombin time is within therapeutic range, achieve hemostasis with 10 to 15 minutes of pressure postoperatively.
 - c. *Factor deficiency*: Patient must be on therapeutic replacement.
 - d. *Thrombocytopenia*: Hemostasis is adequate down to a platelet count of 20,000 unless platelet function is also abnormal (e.g., idiopathic thrombocytopenic purpura).
2. Tetanus status: Document allergies. To prepare sterile field, spiral out from lesion with surgical scrub (isopropyl alcohol is sufficient) and drape.
3. Punch biopsy patients must keep wound clean and dry for 24 hours. After that, keep wound clean and dry except to gently remove crust with warm soap and water twice a day until the suture removal. This minimizes scar width.

Equipment

1. Punches, 1 to 6 mm
2. Scalpel
3. Blades
4. Scissors
5. Forceps
6. Formalin
7. 1% or 2% lidocaine with or without epinephrine
8. Syringes
9. Needles
10. Surgical scrub
11. Drapes
12. Sterile gloves
13. Monofilament suture
14. Electric cautery
15. AgNO₃ sticks. For epidermal lesions only. Use in dermis will tattoo.

Anesthesia

1. 1% lidocaine if the patient is not allergic
2. May use epinephrine if not contraindicated by
 - a. Site: Avoid use in nose, ears, fingers, toes, and genitalia.
 - b. Medical contraindications: coronary artery disease, uncontrolled hypertension, allergy
3. Preoperative acetaminophen (1000 mg) or ibuprofen (400 mg) ½ to 2 hours prior to procedure
4. Postoperative acetaminophen or ibuprofen. Narcotics are rarely necessary.

Precautions

Lesions suspicious for melanoma may be better managed by referral to a physician skilled in managing melanoma.

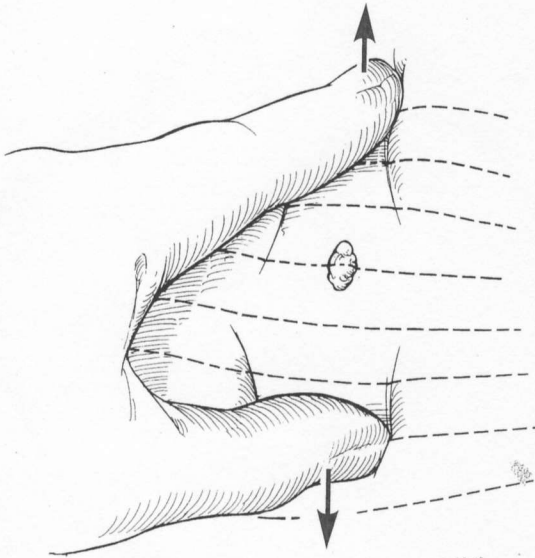
WARNING

- **Do not use epinephrine on nose, ears, fingers, toes, or genitals.**
- **Do not use cautery on the plantar surface of the foot.**
- **Use universal precautions.**

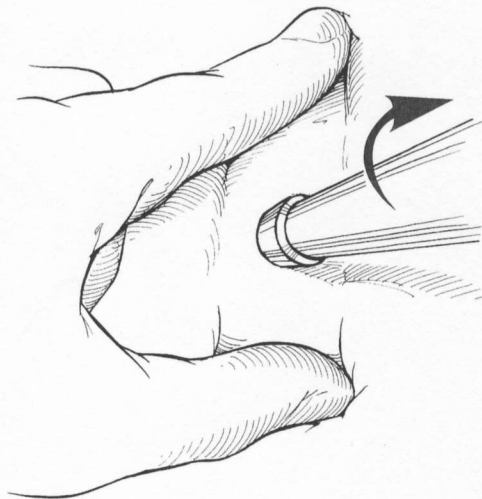
Technique

Punch Biopsy

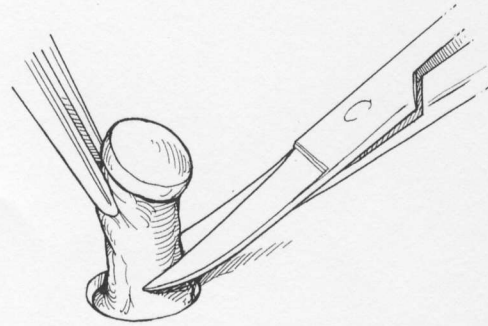
1. Select a punch slightly larger than the lesion if complete excision is the goal. Otherwise, plan the punch to be as small as possible and yet obtain adequate tissue for diagnosis.
2. Diagnosis of blistering diseases and keratoacanthoma requires contiguous, normal tissue to be present. Estimate the depth of the lesion by its color and palpation.
3. Put tension on the skin perpendicular to the observed skin tension lines to create an elliptical wound.



4. Insert the punch with a continuous, clockwise twist to the necessary depth.



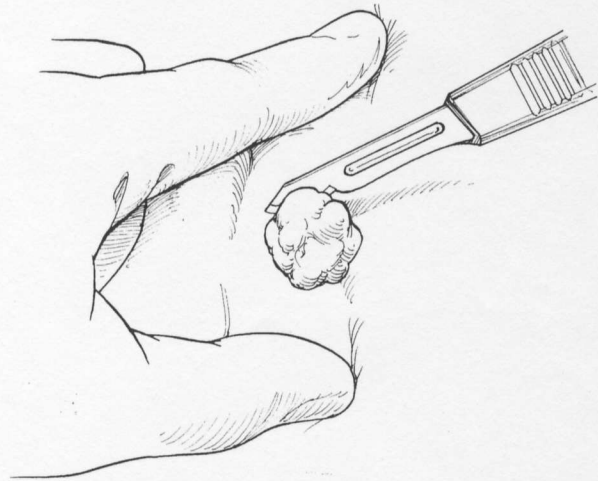
5. Gently extract the tissue column with forceps and remove it from its base in the subepidermal fat with scissors or a scalpel blade.



6. Repair with monofilament suture matched to skin type and site. Hide the scar along the skin tension lines; 5- and 6-mm wounds may need two interrupted stitches.
7. Cleanse the wound, apply a dry, nonocclusive dressing without medication, creams, or ointments to enhance re-epithelialization without infection and prevent scar widening from direct cellular toxicity.

Shave Biopsy

1. *Seborrheic keratosis*: Carefully grasp seborrheic keratosis with forceps, and gently remove by gliding the scalpel blade parallel to the skin surface at the level of the epidermis.



Lightly cauterize.

2. *Verruca (warts)*
 - a. Shave verruca and further pare until punctate bleeding appears.
 - b. Light cauterization followed by scraping out the residual, sticky material will destroy the remaining wart. Do not use cauterization on plantar warts because it may induce painful, permanent scarring.
 - c. Mild acids or vesicants, such as trichloroacetic acid 10% to 35% or salicylic acid paste or plaster, may be applied and weekly paring continued until the wart is destroyed.
3. *Actinic keratosis*
 - a. Remove actinic keratosis by scraping with a blade held perpendicularly to the skin.
 - b. Push the buttery material into a specimen container to confirm the diagnosis and rule out basal

cell carcinoma. The usual tensile resistance of the underlying normal tissue is felt against the blade when all the actinic tissue has been removed.

- c. Light cautery destroys any remaining abnormal cells and is hemostatic.
- d. After cleansing, apply a dry, nonocclusive dressing without medication, creams, or ointments to allow re-epithelialization without infection and prevent scar widening from cellular toxicity.

Follow-Up

Follow at 5 to 10 days based on the expected time for suture removal or crust resolution.

1. Inspect for infection and tensile strength.
2. Remove sutures; alternate if necessary.
3. Discuss pathology. Malignant lesions minimally require yearly follow-up with a complete body inventory. Refer as needed.
4. Review cosmetic instructions.

5. Rub wound gently with hand cream at least twice a day for 6 weeks and up to 1 year. This alleviates redness and minimizes the thickness and stiffness of the scar.
6. Gently remove crust with warm soap and water to minimize scar width.
7. Protect from ultraviolet (UV) radiation with sunscreen 40 for 1 year until scar repigmentation is complete.

B

Bibliography

- Fitzpatrick TB, Eisen AZ, Wolff K, et al: *Dermatology in General Medicine*. New York, McGraw-Hill, 1979, pp 35–36.
- Fitzpatrick TB, Polano MK, Suurmond D: *Color Atlas and Synopsis of Clinical Dermatology*. New York, McGraw-Hill, 1983.
- Gilman AG, Goodman LS, Gilman A: *Goodman and Gilman's The Pharmacological Basis of Therapeutics*. New York, Macmillan, 1985, p 951.
- Moschella SL, Hurley HJ: *Dermatology*, vols 1 and 2. Philadelphia, WB Saunders, 1985, pp 2010–2013.